

TITLE OF PAPER : ADVANCED MIDWIFERY SCIENCE

FINAL EXAMINATION : NOVEMBER, 2019

COURSE CODE : MWF 609

DURATION : THREE (3) HOURS

TOTAL MARKS : 100

INSTRUCTIONS:

- 1. ANSWER ALL QUESTIONS**
- 2. FIGURES IN BRACKETS INDICATE MARKS ALLOCATED TO EACH OR PART OF A QUESTION**
- 3. ANSWER EACH QUESTION ON A NEW PAGE**

QUESTION 1

Dudu, a 16 year old primigravida at term pregnancy is brought to a rural clinic; she is unresponsive, cyanotic, coughs, her face is oedematous and her grandmother informs the midwife that Dudu has not passed urine since last night; she was complaining of severe headache and has been in a state of confusion since yesterday. Dudu has no clinic records and her grandmother was not aware of her pregnancy.

1.1 Describe the patho-physiology that causes the manifestations described in Dudu above as she had been diagnosed with severe preeclampsia.

15 Marks

1.2 Describe clinical evidence that will be conducted by an advanced midwife to ensure that Dudu's foetus is growing well.

10 marks

Question 2

Zozo is a grand multipara client who is in the latent phase of labour. She was advised by a midwife to ambulate in order to accelerate her labour. She called out for help as her membranes ruptured spontaneously and a gush of amniotic fluid escaped.

2.1 State emergency interventions that will be instituted by the advanced midwife before the arrival of the obstetrician.

10 marks

2.2 Discuss possible course of labour following excessive reduction of amniotic fluid; refer to the case study provided.

15 Marks

Question 3

Thoko, a seventeen (17) year old primigravida at term pregnancy is referred to the National referral maternity ward (level 3 maternity ward) after she had been in labour for 6 hours at a Health Centre (level 2 maternity centre). The information recorded on the partograph shows that she was evaluated once at 2pm; the lie of the foetus was longitudinal, cephalic presentation 3/5, position left occipito-posterior, foetal heart 110, vaginal examination findings are as follows: cervix 4cm dilated, membranes ruptured, draining meconium stained liquor; the anterior fontanelle felt but moulding was difficult to detect because of caput succedaneum. Uterine contractions, Maternal vital signs and urine results were not recorded.

An advanced midwife examined the client at 5 pm and provided the following findings: maternal vital signs; Blood pressure, 110/70, pulse 100, temperature 38.6 degrees Celsius. FHH 90 beats per minute. Presentation cephalic, position left occipito-lateral. Vaginal examination findings were the following: vagina hot and dry, cervix 5cm, loosely applied to the presenting part, station at 0, sagittal sutures caught at the transverse diameter of the outlet; fresh meconium stained liquor draining. Urine negative glucose + albumen, volume 100 ml

3.1 Chart the information provided on a partograph

5 marks

3.2 Discuss the advanced midwives' intervention based on the information plotted on the partograph; provide a scientific rationale for your responses.

10 Marks

3.3 State the prognosis of the client, should interventions be delayed. Provide a rationale for your responses.

10 marks

Question 4

Sonile, a grand-multiparous client who progressed fast in labour (two hours) and delivered twins; one alive and the other was a macerated stillbirth. Ten minutes post-delivery, Sonile bleed profusely from the genital tract.

10 marks

4.1 State two (2) **main** risk factors for postpartum haemorrhage as presented in the case study, provide scientific rationales in your discussion.

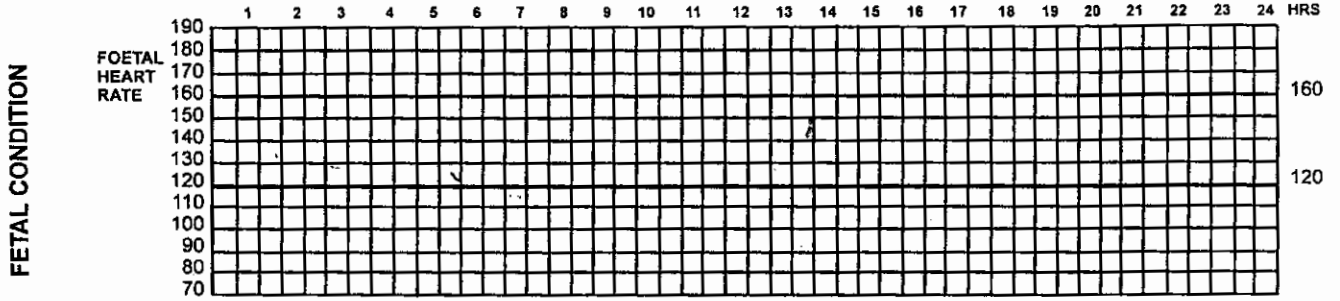
10 marks

4.2 Discuss the management of shock caused by massive obstetric haemorrhage, as presented in the case study.

15 marks


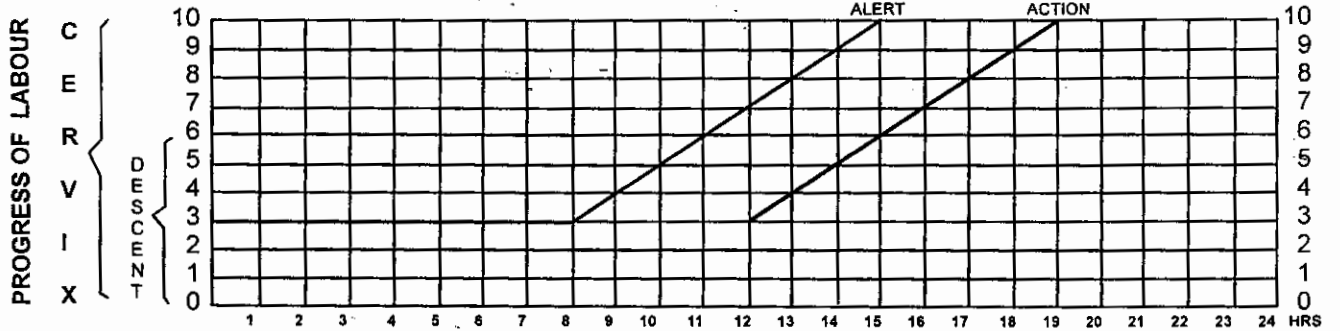
SWAZILAND GOVERNMENT LABOUR RECORD

NAME AGE HOSPITAL No.
 PARITY: ALIVE: SB/NND ABORTIONS EDD HEIGHT CMS
 PELVIS ADEQUATE / BORDERLINE. RISK FACTORS:
 REGULAR CONTRACTIONS STARTED AT: MEMBRANES RUPTURED AT



LIQUOR MOULDING

1	2	3	4	5	6	7	8	9	10	11	12	13	14	15	16	17	18	19	20	21	22	23	24
---	---	---	---	---	---	---	---	---	----	----	----	----	----	----	----	----	----	----	----	----	----	----	----



DRUGS ORAL AND I.V. FLUIDS

OXYTOCIN Units/L.

